

Mandibular Third Molars and Their Influence on Mandibular Angle Fracture Fixation

ARJUNAN KUMARAN¹, WEN CHAO CHEW², CHOR HOONG HING³, WINSTON TAN⁴, THIAM CHYE LIM⁵

ABSTRACT

Introduction: Mandibular fractures occur commonly in Singapore and 32% involve the angle. The third molar (M3) predisposes the angle to fracture and is often involved in the fracture site. During fixation, it is often routinely retained but few studies question if this impacts surgical repair and post-operative healing and recommend if it should continue to be done.

Aim: To describe all operatively treated mandibular angle fractures (MAFs) with M3 retention over 10 years in a single centre and report any effect of routine M3 retention on fracture fixation or post-operative complications.

Materials And Methods: The present study is a retrospective one including all operatively treated MAFs with M3 retention in the National University Hospital, Singapore between January 2001 and December 2010. Subjects below 16 years of age and those with incomplete follow up or Computed Tomography

(CT) data were excluded. Hospital records were reviewed for demographic variables and (Seeman's 7) postoperative complications. OsiriX version 7.5 (Pixmeo., Switzerland) used to characterise the fracture and M3. Analysis was performed using Statistical Package for Social Sciences version 23 (IBM, USA).

Results: 23 cases (25 MAFs) were included and the average subject was a 28.8 (SD 4.59) year old male (88%) with a left (64%) simple (84%) MAF with fracture line involving the M3 socket (76%). Concomitant mandibular fractures featured in 14 cases (56%). Most M3 were Class II (76%), Class B (68%) and distoangular (52%). Mean intraosseous M3 length and diameter was 8.33mm (SD 2.09) and 11.70mm (SD 1.89) respectively. The mean mandibular thickness and width was 29.25mm (SD 5.41) and 16.92mm (SD 2.03) respectively. Despite M3s of varying morphology, successful repair was carried out in all cases.

Conclusion: Unless the M3 impedes fixation, it need not be removed during fracture fixation.

Keywords: Molar, Mandible, Surgery

INTRODUCTION

The projected position of the mandible in the maxillofacial skeleton renders it highly susceptible to trauma [1,2]. Though symphyseal and parasymphseal fractures predominate locally [3], fractures of the mandibular angle are also relatively common [4] as it is a point of mechanical weakness [5,6]. This is because its sharp angulation concentrates stress at the transition zone between dentate and edentate regions within the mandible and its thicker upper border and thinner basilar bone result in an area of low resistance [7]. An impacted third molar (M3) further contributes to this by interrupting force transmission along the external oblique ridge and decreasing bone mass by occupying osseous volume [2].

In the National University Hospital, like many others, the vast majority of mandibular angle fractures are conservatively managed and the M3 routinely left in situ. When surgery is considered, mandibular angle fracture (MAF) fixation aims to restore function through primary bony union with either open or closed reduction with or without rigid fixation [8,9]. Controversy still remains over the relative effectiveness of each technique and its indications [9,10] and the literature becomes even less clear when the M3 is involved in the fracture site [10,11]. Presently, surgeons from the department perform open reduction with rigid fixation and routinely retain the M3.

As an impacted M3 is already an established risk factor for sustaining fractures and is often left in situ, this study instead aims to report any complications seen when it is routinely retained during repair. It also aims to discuss the M3's role in fracture fixation technique and post-operative healing as well as recommend if surgeons should consider changing the current practice of routinely retaining them in the fracture site during repair.

MATERIALS AND METHODS

This retrospective study analysed the demographic data and Computed Tomography (CT) scans of 23 subjects with 25 MAFs

(2 subjects had bilateral MAFs). These subjects were selected from an existing local database of patients admitted to the Plastic, Reconstructive and Aesthetic Surgery department of a single centre (National University Hospital, NUH, Singapore) between January 2001 to December 2010. All subjects underwent open reduction with rigid fixation with M3 retention, were discharged well and subsequently followed up in clinic at one month and six months postoperatively.

Inclusion and Exclusion Criteria: Subjects below 16 years of age and those managed conservatively were excluded. Hospital records and CT images of these subjects were then retrieved and reviewed. Only those with complete follow up (six months postoperatively) and adequate CT scan Digital Imaging and Communication in Medicine (DICOM) data were included in the analysis. Subjects with bilateral mandibular angle fractures were logged as separate entries.

Ethics Approval: Informed consent was obtained from all individual participants included in the study. All personal identifiers were removed and no intervention, harm or additional cost to the subjects was incurred. The study conformed to the tenets of the Declaration of Helsinki and was approved by the National University Hospital. The present study does not contain any studies with animals performed by any of the authors. All authors declare that they have no conflicts of interest.

Variables Collected: Demographic data were retrieved from hospital records and included age, gender and smoking status. Clinical data extracted included the presence of Seemann's seven major postoperative complications, namely, osteosynthesis failure, pseudoarthrosis, infection, neurological deficits, wound-healing disturbance, functional impairment and dis-occlusion [12].

CT Measurements: DICOM image viewing software OsiriX version 7.5 (Pixmeo., Switzerland) was used to read the fine cut (1mm interval) CT images, measure variables and generate 3 dimensional (3D) surface renders of the subject's maxillofacial skeleton.

The generated 3D surface render was rotated, translated and magnified to allow adequate visualisation of the MAF and M3. MAF data collected included degree of comminution, position of fracture line relative to M3 socket and the presence of concomitant fractures. M3 data collected included the presence, (horizontal and vertical) orientation, angulation and intraosseous length and diameter. Horizontal and vertical orientation was categorised according to Gregory and Pell's Classification [13] [Table/Fig-1] and angulation categorised according to Winter's Classification [14] [Table/Fig-2].

Horizontal	Amount of Space Between Ramus and Second Molar
Class I	Adequate Space for Eruption
Class II	Inadequate Space for Eruption
Class III	Third Molar Located Partially or Completely in Ramus
Vertical	Relationship of Third Molar Crown to Second Molar Crown
Class A	Level at #OP
Class B	Between ^CE of The Second Molar and #OP
Class C	No Third Molar
Class O	Long axis of M3 is in opposite direction to M2

#OP - Occlusal Plane, ^CE - Cemento-Enamel Junction

[Table/Fig-1]: Gregory and Pell Classification of M3 Impaction.

Angulation	Description
Mesio-angular	M3 is tilted towards M2 in a mesial direction
Disto-angular	Long axis of M3 is angled posteriorly away from M2
Horizontal	Long axis of M3 is horizontal
Vertical	Long axis of M3 is parallel to long axis of M2
Buccal	M3 is tilted in buccal direction
Lingual	M3 is tilted in a lingual direction
Transverse	M3 is horizontally impacted in a buccal-lingual orientation
Inverse	Long axis of M3 is in opposite direction to M2

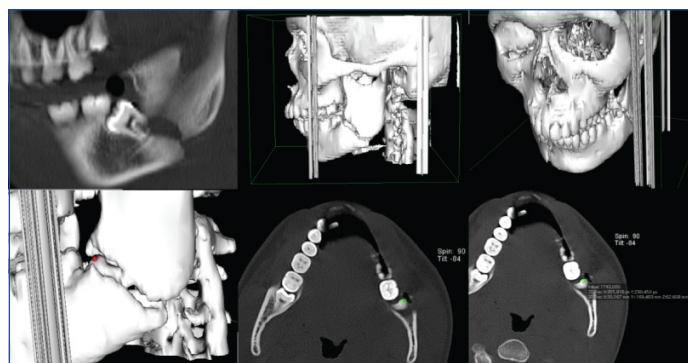
[Table/Fig-2]: Winter's Classification of M3 Angulation.

As a surrogate measure of osseous volume occupied by the M3 vertically and horizontally, the ratio of the intraosseous M3 length to mandibular height and intraosseous M3 diameter to mandibular width were used respectively. To measure these variables, points were placed in 3D space on the surface render and calculations performed using the coordinates of these points. Correct and precise placement was confirmed by checking the position of these points on both the two dimensional (2D) CT scan image and 3D surface render as well as the use of reference lines.

Specifically, for intraosseous M3 length, the surface render was manipulated to view the M3 within the mandible and one point each was placed on the highest and lowest part of the tooth. The line formed by these two points was approximately perpendicular to the long axis of the body. For mandibular height, one point each was placed on the most superior and most inferior point of the body adjacent to the M3. The line formed by these two points was approximately perpendicular to the long axis of the body as well.

Similarly, for intraosseous M3 diameter, the surface render was manipulated and a point each was placed on the most medial and lateral aspect of M3 within the mandible. The line formed between these two points was perpendicular to the long axis of the ramus. For mandibular width, a point each was placed on the most medial and lateral aspect of the body adjacent to the M3. The line formed by these two points was perpendicular to the long axis of the ramus as well.

The coordinates of these points in x, y, z format were input into Excel (Microsoft®, Washington) and distances calculated. Screenshots of the OsiriX interface, 3D generated surface render, point placement and coordinates reading [Table/Fig-3].



[Table/Fig-3]: Screenshots of OsiriX Interface, 3D Generated Surface Render, Point Placement and Coordinates Reading.

STATISTICAL ANALYSIS

The database was constructed and analysis performed using Statistical Package for Social Sciences (SPSS) version 23.0 (IBM Corp., Armonk, NY). Parametric tests were performed and statistical significance set at $p < 0.05$.

RESULTS

Of the 55 identified MAFs operated on between January 2001 and December 2010, 23 subjects (with 25 MAFs) had complete follow up and adequate CT scan DICOM data and were included in the study.

Most subjects were male (22, 88%) with a mean age of 28.8 (SD 4.59) years. MAFs were more commonly on the left (14, 56%) and not comminuted (21, 84%). Majority of fracture lines involved the M3 socket (19, 76%) and when they did not, fracture lines posterior (5, 20%) to the socket occurred more commonly. Concomitant mandibular fractures were seen in 14 cases (56%) and consisted of nine parasymphiseal, four symphyseal and one body fractures. Excluding symphyseal fractures, nine out of 10 concomitant fractures occurred contralateral to the angle fracture. Most M3 teeth were Class II (76%), Class B (68%) (Gregory and Pell) and distoangular (52%) (Winter's). These results have been summarised below in [Table/Fig-4].

The mean intraosseous M3 length and diameter was 8.33 mm (SD 2.09) and 11.70 mm (SD 1.89) respectively. The mean mandibular height and width was 29.25 mm (SD 5.41) and 16.92 mm (SD 2.03) respectively [Table/Fig-5].

Of Seeman's seven major postoperative complications, periodontitis was seen in one subject post-operatively. This resolved with outpatient antibiotics and was not seen at six months post operation. All 25 MAFs were operatively repaired with good clinical outcomes at six months postoperatively [Table/Fig-6].

In the present study, left sided simple MAFs with fracture lines passing through the M3 socket predominated. The M3s were commonly class II, class B and lingoverted. The most common concomitant fracture was a contralateral parasymphiseal one. The mean mandibular thickness and width were 29.25 mm and 16.92 mm respectively. The mean osseous volumes occupied by M3 vertically and horizontally were 23.8% and 70.1% respectively.

All 25 MAFs were treated successfully with open reduction with rigid fixation with good clinical outcomes and no complications at six months post operation. One subject with poor pre-operative hygiene did develop mild periodontitis immediately post-operatively but this resolved with oral antibiotics. He did not have any signs of periodontitis at the one or six month follow up appointments. Hence, despite M3s of various morphologies and even in a case of poor-preoperative oral hygiene, successful fixation with M3 retention without long term complication was possible. A similar result was also seen by Lim HY et al., [15] in their study.

However, in the literature, treatment of MAFs has been reported to give rise to the highest frequency of postoperative complications, up to 32% [10, 16]. This opinion is shared by Mehra P et al., [17] who suggest that M3 retention instead increases infection risk due to

Subject	Demographics			MAF			M3		
	Age	Gender	Smoking habit	Comminution	Concomitant fractures	Fracture line in relation to	Horizontal position	Vertical position	Angulation
		(M/F)	(Y/N)	(Y/N)		M3 socket	(I/II/III)	(A/B/C)	(M/D/H/V)
1	37	M	N	N	Y	In line	II	B	D
2	26	M	Y	N	N	In line	II	B	V
3	27	M	N	N	N	Anterior	I	C	D
4	30	F	N	N	Y	In line	III	B	D
5	24	M	N	Y	N	Posterior	II	A	V
6	29	M	N	N	Y	In line	II	B	M
7	28	M	N	N	Y	In line	I	B	M
8	25	M	N	N	Y	In line	II	B	D
9	26	M	N	Y	N	Posterior	II	C	D
10	27	M	N	Y	Y	Posterior	II	A	M
11	35	M	N	N	N	In line	II	A	M
12	29	M	N	N	N	Posterior	II	B	H
13	30	F	N	N	N	In line	II	B	M
14	28	M	N	N	Y	In line	II	B	D
15	25	M	N	N	Y	In line	I	A	H
16	29	M	N	N	Y	In line	II	B	V
17	30	M	N	N	N	Posterior	II	B	M
18	28	M	N	N	Y	In line	II	A	D
19	24	M	N	N	N	In line	II	B	D
20	21	M	N	N	N	In line	II	B	D
21	42	M	N	N	Y	In line	II	B	D
22	28	M	N	N	Y	In line	II	B	D
22	28	M	N	N	N	In line	I	A	H
23	32	M	N	Y	Y	In line	I	B	D
23	32	M	N	N	Y	In line	II	B	D

[Table/Fig-4]: Demographic, MAF and M3 Data of All 25 MAFs.
(patient 22 and 23 had more than one MAF)

M3 Variable	Mean (SD)
Intraosseous M3 Length (L), mm	8.33 (2.09)
Mandibular Height (H), mm	29.25 (5.41)
Ratio of L/H	0.29 (0.07)
Intraosseous M3 Diameter (D), mm	11.70 (1.89)
Mandibular Width (W), mm	16.92 (2.03)
Ratio D/W	0.70 (0.13)

[Table/Fig-5]: Osseous Volume Occupied by M3.

intraoral communication through the periodontal ligament, allowing ingress of bacteria-laden saliva into the fracture site postoperatively. In addition, breach of the periodontal tissue during the initial trauma may occur making the attached gingiva susceptible to pocket formation and further periodontitis.

The M3 itself may serve as a nidus for micro-organisms [18] and this may be especially so in cases of poor M3 viability following the trauma, existing pulpal, periodontal or periapical pathology or manipulation during fixation surgery. Teeth can be determined

Mandibular Angle Fractures (n=25)					
Demographic			M3		
Age, years (SD)			Gregory and Pell Classification		
Gender			Horizontal		
Male			Class I		
Female			Class II		
Smoking			Class III		
MAF			Vertical		
Comminution			Class A		
Concomitant Fractures			Class B		
			Class C		
Fracture line in relation to			Winter's Classification		
M3 socket			Angulation		
Anterior			Mesio-angular		
In line			Disto-angular		
Posterior			Horizontal		
Fracture line in relation to			Vertical		
M3 socket			Others		
Anterior					
In line					
Posterior					

[Table/Fig-6]: Summary of Demographic, MAF and M3 Data of all 25 MAFs.

non-viable if the crown or roots are fractured, there is an infection or dental carries or on electric pulp testing. Postoperatively, this can be as high as 26.6% but only a quarter of these non-viable M3s remained so after six months [19]. This was attributed to manipulation of fracture pieces during reduction and the raising of a mucoperiosteal flap for fixation.

With regards to the impact of M3 on fracture reduction, fixation and healing, difficulties during the procedure and osteosynthesis failure were not encountered in the study even at six months post operation. Sachin Rai et al., [18] observed more occlusal discrepancy after M3 removal. Ellis E [19] and Rubin M M et al., [20] have reported similar results where there are similar complication rates in both retained and removed M3s. This suggested retention may confer some benefit in fracture healing. However, it is difficult to draw conclusions from the study size was small, short-term, non-randomised and did not take into account the full 3D orientation of the M3.

The authors believe retention of the M3 in fact aids surgical treatment of MAFs. It provides a reference for proper alignment of dentition and bone and fixation of the fracture fragments. The M3 also serves as a posterior stop when manipulating the fragments so over or under reduction does not occur. Retention increases the surface area of contact between the fragments allowing for greater buttressing effect. Conversely, after M3 removal the resultant greater discontinuity in contact may account for the poorer outcomes.

Despite the inclusion of fractures and M3s of differing types and characteristics in the present study, none of the patients developed post-operative complications. The authors believe this is due to the strict treatment protocol that was employed. In the literature, prophylactic antibiotics and daily chlorhexidine oral wash is prescribed to ensure asepsis and proper hygiene [7]. In the study, open reduction and rigid fixation was performed appropriately and adequately. Hence, none of the patients suffered non-union or malunion of fracture fragments.

LIMITATIONS

Though this study is limited by its size, it suggests the presence and characteristics of the M3 which do not influence the incidence of postoperative complications.

CONCLUSION

Several criteria for M3 removal have been suggested, including non-viability, instability within fracture site and impedance of reduction of fracture fragments [15]. The authors agreed and recommend that the M3 need not be removed unless the tooth itself is broken or if it impedes fixation.

REFERENCES

- [1] Inaoka SD, Careiro SC, Vasconcelos BC, Leal J, Porto GG. Relationship between mandibular fracture and impacted lower third molar. *Med Oral Patol Oral Cir Bucal*. 2009;14(7):349-54.
- [2] Bezerra TP, Studart-Soares EC, Pita-Neto IC, Costa FW, Batista SH. Do third molars weaken the mandibular angle? *Med Oral Patol Oral Cir Bucal*. 2011;16(5):657-63.
- [3] Tay AG, Yeow VK, Tan BK, Sng K, Huang MH, Foo CL. A review of mandibular fractures in a craniomaxillofacial trauma centre. *Ann Acad Med Singapore*. 1999;28(5):630-33.
- [4] Ellis E 3rd. Treatment methods for fractures of the mandibular angle. *Int J Oral Maxillofac Surg*. 1999 Aug;28(4):243-52.
- [5] Duan DH, Zhang Y. Does the presence of mandibular third molars increase the risk of angle fracture and simultaneously decrease the risk of condylar fracture? *Int J Oral Maxillofac Surg*. 2008 Jan;37(1):25-28.
- [6] Adeyemo WL. Do pathologies associated with impacted lower third molars justify prophylactic removal? A critical review of the literature. *Oral Surg Oral Med Oral Pathol Radiol Endod* 2006 Oct;102(4):448-52.
- [7] Chrcanovic BR, Custódio AL. Considerations of mandibular angle fractures during and after surgery for removal of third molars: a review of the literature. *Oral Maxillofac Surg*. 2010 Jun;14(2):71-80. DOI: 10.1007/s10006-009-0201-5.
- [8] Lee JH. Treatment of Mandibular Angle Fractures. *Arch Craniofac Surgery*. 2017 Jun;18(2):73-75.
- [9] An W, Ainiwaer A, Wusiman P, Ali G, Moming A. Surgical Management of Mandibular Angle Fractures. *J Craniofac Surg*. 2018 Mar 20. DOI 10.1097/SCS.0000000000004568. [Epub ahead of print].
- [10] Chen CL, Zenga J, Patel R, Branham G. Complications and Reoperations in Mandibular Angle Fractures. *JAMA Facial Plast Surg*. 2018 May 1;20(3):238-243. DI: 10.1001/jamafacial.2017.2227.
- [11] Ferreira E Costa R, Oliveira MR, Gabrielli MAC, Pereira-Fi;ho VA, Viera EH. *J Craniofac Surg*. 2018 Mar 13. DOI: 10.1097/SCS.0000000000004484. [Epub ahead of print].
- [12] Seeman R, Schicho K, Wutzl A, Koenig G, Poeschi WP, Krennmaier G, et al. Complication rates in the operative treatment of mandibular angle fractures: a 10-year retrospective. *J Oral Maxillofac Surg*. 2010 Mar;68(3):647-50. DOI: 10.1016/j.joms.2009.07.109.
- [13] Pell G, Gregory G. Impacted mandibular third molars, classification and modified technique for removal. *Dental Digest* 1933;39(9):330-38.
- [14] Yilmaz S, Adisen MZ, Misirlioglu M, Yorubulut S. Assessment of Third Molar Impaction Pattern and Associated Clinical Symptoms in a Central Anatolian Turkish Population. *Med Princ Pract*. 2016;25(2):169-75. DOI: 10.1159/000442416.
- [15] Lim HY, Jung TY, Park SJ. Evaluation of postoperative complications according to treatment of third molars in mandibular angle fracture. *J Korean Assoc Oral Maxillofac Surg*. 2017 Feb;43(1):37-41.
- [16] Berg S, Pape HD. Teeth in fracture line. *Int J Oral Maxillofac Surg*. 1992 Jun;21(3):145-6.
- [17] Mehra P, Murad H. Internal fixation of mandibular angle fractures: a comparison of 2 techniques. *J Oral Maxillofac Surg*. 2008 Nov;66(11):2254-60. DOI: 10.1016/j.joms.2008.06.024.
- [18] Rai S, Pradhan R. Tooth in the line of fracture: Its prognosis and its effects on healing. *Indian J Dent Res*. 2011 May-Jun;22(3):495-6. DOI: 10.4103/0970-9290.87083.
- [19] Ellis E 3rd. Outcomes of patients with teeth in the line of mandibular angle fractures treated with stable internal fixation. *J Oral Maxillofac Surg*. 2002 Aug;60(8):863-65.
- [20] Rubin MM, Koll TJ, Sadoff RS. Morbidity associated with incompletely erupted third molars in the line of mandibular fractures. *J Oral Maxillofac Surg*. 1990 Oct;48(10):1045-47.

PARTICULARS OF CONTRIBUTORS:

1. Medical Officer, Department of Plastics, Reconstructive and Aesthetic Surgery, National University Hospital, Singapore.
2. Medical Officer, Department of Plastics, Reconstructive and Aesthetic Surgery, National University Hospital, Singapore.
3. Research Coordinator, Department of Plastics, Reconstructive and Aesthetic Surgery, National University Hospital, Singapore.
4. Oral Maxillofacial Surgeon, Department of Plastics, Reconstructive and Aesthetic Surgery, National University Hospital, Singapore.
5. Plastic Surgeon, Department of Plastics, Reconstructive and Aesthetic Surgery, National University Hospital, Singapore.

NAME, ADDRESS, E-MAIL ID OF THE CORRESPONDING AUTHOR:

Ms. Arjunan Kumaran,
5 Lower Kent Ridge Road, Singapore.
E-mail: arjunankumaran@gmail.com

FINANCIAL OR OTHER COMPETING INTERESTS: None.

Date of Submission: **Apr 10, 2018**
Date of Peer Review: **June 05, 2018**
Date of Acceptance: **July 31, 2018**
Date of Publishing: **Jan 01, 2019**